

## Herpesviridae

Marek's disease virus, Pseudorabies virus, Infectious laryngotracheitis virus, Bovine herpes viruses, Equine herpes viruses, Malignant catarrhal fever virus, Duck plague virus

Latin '**Herpein**' = To creep

### Group I: dsDNA viruses

Order: **Herpesvirales**

Family: **Herpesviridae**

Subfamily: Alphaherpesvirinae

Genus: Iltovirus

**Gallid alphaherpesvirus 1**    **Infectious laryngotracheitis**

Mardivirus

**Gallid alphaherpesvirus 2**    **Marek's Disease Virus**

Simplexvirus

Varicellovirus

**Suid/porcine Herpesvirus 1**    **Pseudorabies virus**

Subfamily: Betaherpesvirinae

Genus: Roseolovirus

**Human betaherpesvirus 6A, 6B, 7**

Subfamily: Gammaherpesvirinae

Genus: Lymphocryptovirus

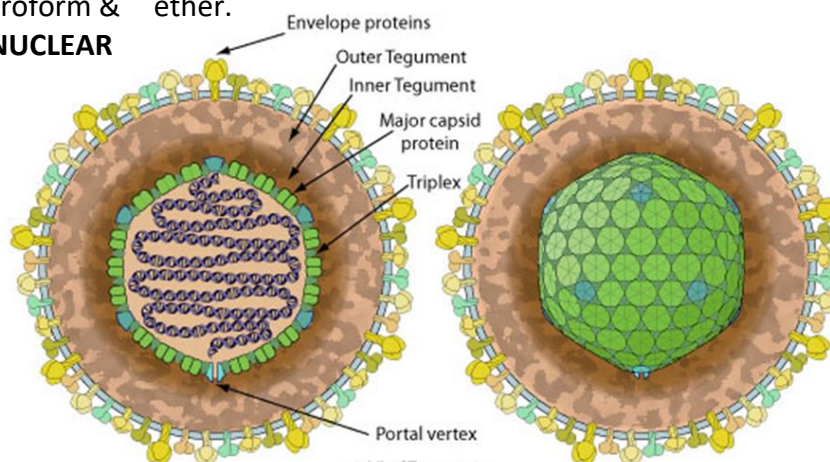
Rhadinovirus

Macavirus ,

Percavirus

### Properties of Herpesvirus

- Enveloped,
- spherical to pleomorphic,
- 150-200 nm in diameter,
- **Icosahedral symmetry.**
- Capsid consists of 162 capsomers and is surrounded by an amorphous tegument.
- Glycoproteins complexes are embed in the lipid envelope.
- Genome-complex consists of single linear molecule of double stranded DNA, **125-135 Kbp** in size. (Infectious under appropriate experimental conditions).
- Sensitive to chloroform & ether.
- **REPLICATION : NUCLEAR**



### Infectious Laryngotracheitis

- Infectious laryngotracheitis (ILT) is a **highly contagious upper respiratory tract** disease of chicken caused by a Gallid herpesvirus 1 (GaHV-1) belonging to the genus Iltovirus, and subfamily Alphaherpesvirinae within Herpesviridae family.
- The disease is characterized by **conjunctivitis, sinusitis, oculo-nasal discharge, respiratory distress, bloody mucus, swollen orbital sinuses, high morbidity**, considerable mortality and decreased egg production.
- It is well established in highly dense poultry producing areas of the world due to characteristic **latency and carrier status of the virus**.
- **Co-infections with other respiratory pathogens** and environmental factors adversely affect the respiratory system and prolong the course of the disease.

### Pathogenicity

The replication of ILTV occurs during the first week of infection. **Conjunctiva and tracheal mucosa are the major sites of ILTV replication** leading to inflammation, serous or mucoid discharge, and respiratory distress.

As ILTV first interacts with the cells lining the nasal cavity, conjunctival mucosa and harderian glands, these tissues play a pivotal role in early virus replication and dictate the fate of infection .

Within respiratory system, the epithelial cells that lines larynx and trachea are always affected, while respiratory sinuses, air sacs and lung tissues **may or may not** be affected

### Physico-chemical properties

**Enveloped nature of the virus**, the infectivity of ILTV is greatly modulated by organic solvents such as chloroform, ether and **oxidizing agents like H<sub>2</sub>O<sub>2</sub>**.

The sensitivity of ILTV to the temperature differs .

In respiratory exudates and chicken carcasses, the **virus can remain infective for 10 days to 3 months** at a temperature range of 13-23 °C.

The loss of infectivity of ILTV by heating at 55 °C for 15 minutes .

**In deep litter, the ILTV survives for 3-20 days at 11-24.5 °C**, in the droppings of battery cages for 3 days at 11–19.5 °C and at least for 3 weeks in buried carcasses.

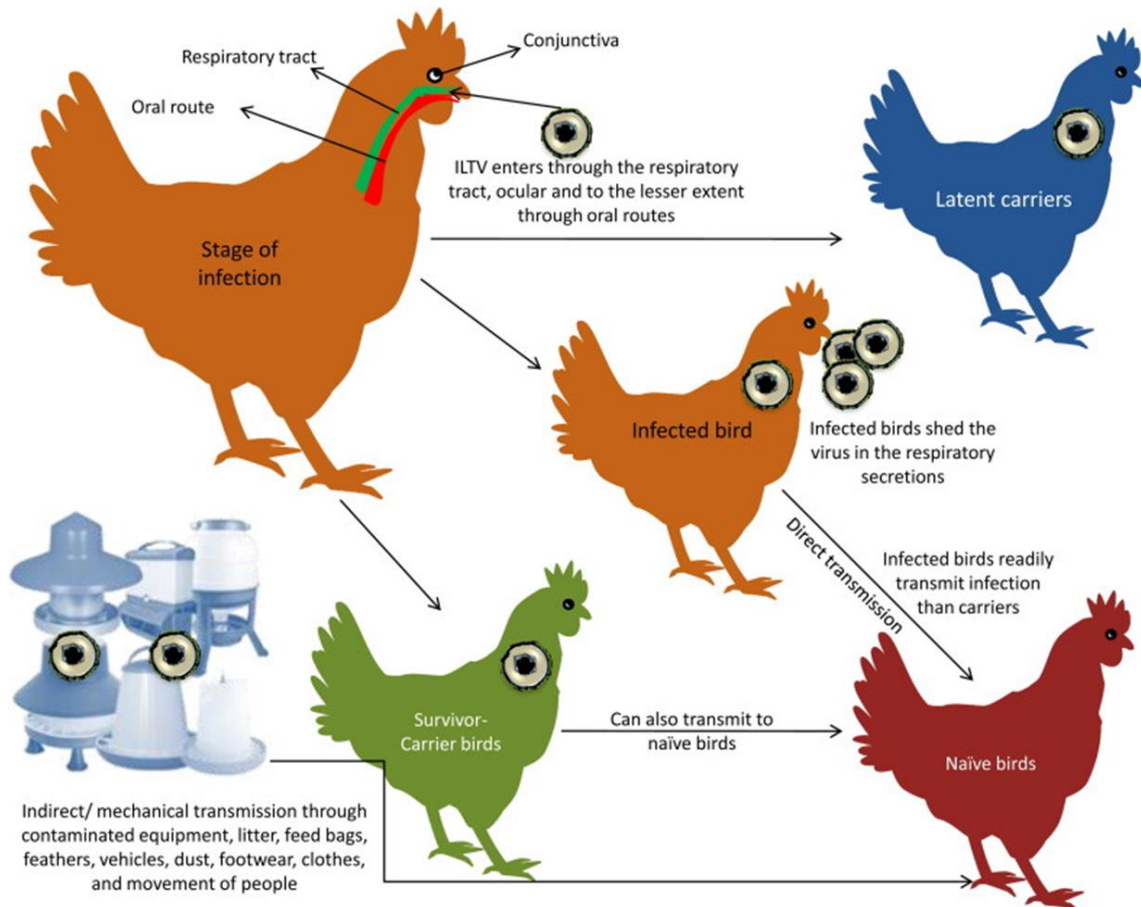
The virus gets readily destroyed (<1 min) by common disinfectants like **3% cresol, 5% phenol or a 1% sodium hydroxide solution**, however the presence of organic matter affects the efficiency of disinfectants.

### Host

- ILTV has got a narrow host range.
- The **main natural host of ILTV is chicken**, however, the infections are also reported in peacocks, pheasants, turkeys and guinea fowl. Ducks are refractory to ILT infection, they can act as carriers.
- Chickens and pheasants are affected by LT. Chickens **14 weeks and older are more susceptible than young chickens**. Most LT outbreaks occur in **mature hens**.
- In recent years, LT has also caused significant respiratory problems **in broilers greater than 3 weeks of age, especially during the cooler seasons of the year**. This is believed to be due to unwanted spread of LTvaccines between poultry flocks.

## Transmission

- Infected birds shed the virus in their respiratory secretions for 10 days post-infection. ILTV enters into the host through the **respiratory tract, ocular and to a lesser extent through oral routes**.
- **Direct bird-to-bird transmission** is rampant in comparison to contact with latently infected or carrier birds.
- **Neither vertical transmission nor transmission of virus through the egg shell** has been demonstrated.



## Pathogenesis

1. The natural portal of entry of ILTV is respiratory and ocular routes.
2. The initial replication takes place in the epithelium of the conjunctiva, respiratory sinuses, larynx and upper respiratory tract.
3. The virus titre peaks between 4 and 6 days post-infection, and the virus can be detected in the latency sites Trigeminal ganglion (TRG) from two of cytolytic infections onwards .
4. The **active cytolytic infection of ILTV results in severe damage to tracheal and conjunctival epithelial lining leading to haemorrhages** and other clinicopathological manifestations in birds. Subsequently, the ILTV disseminates to the underlying lamina propria of the tracheal epithelium after invading through the basement membrane and reaches to the liver, caecal tonsils and cloaca (With the help of upregulated proteases).

5. The virus replication leads to up-regulation of genes related to cell growth and proliferation. **The infected cells produce cytokines and other inflammatory mediators leading to immune responses** such as elevated body temperature, intensive edema, and infiltration of lymphocytes.
6. **ILTV establishes latency in the trigeminal ganglion** corresponding to the induction of effective adaptive immunity following the lytic phase of an infection. **Reactivation of ILTV from latency** is mediated by thymidine kinase and infected-cell polypeptide 4 (ICP4).

### Clinical signs

- The incubation period of ILTV varies between 6 and 14 days
- The clinical course of ILT varies from 11 days to 6 weeks depending on the form of the disease.
- The clinical signs are characterized by **a sudden increase in average daily mortality in the affected flock**. The infection is characterized by **peracute, acute and chronic** forms of ILT.

### Peracute form

- sudden onset of rapid spread and high mortality which may exceed 50%.
- Birds become lethargic, often exhibit moderate-to-severe conjunctivitis with swollen eyelids and increased lacrimation.
- **Dyspnea and gasping with an extension of the head and neck**.
- **Coughing, rattling, and gurgling also noticed when the birds try to expel the clotted blood and debris from the obstructed trachea**. The [clotted blood is also found in cages, feed turfs, walls and floor of the poultry houses](#). The affected birds usually die within 3 days.

### Acute form

- Characteristic dyspnea is commonly noticed in the acute form of ILT, but the onset is not sudden or severe as seen in peracute form.
- Initially, the affected birds become inactive and exhibit anorexia.
- The internal core temperature increases between 4 and 6 days post-infection.
- **Tracheal obstruction with clotted blood and exudates results in a long drawn out gasps with open-mouthed breathing, high-pitched squawk and moist rales**. Birds extend their head and neck to facilitate breathing (commonly referred to as "**pump handle respiration**").
- Inhalation produces a **wheezing and gurgling sound**.
- Blood-tinged exudates and serum clots are expelled from the trachea of affected birds.
- Many birds die from asphyxiation due to a blockage of the trachea.
- The affected birds may also show **purulent conjunctivitis with frothy exudates in the inner canthus of the eye, sinusitis and nasal discharge**.
- The **morbidity may reach 100% and the mortality varies from 10 to 30%**, which may last up to 15 days. Varying **level of egg production is noticed in layer flocks**, some flocks may experience the **complete cessation of egg production**, which may recover to the normal level in due course of time.




### Chronic form

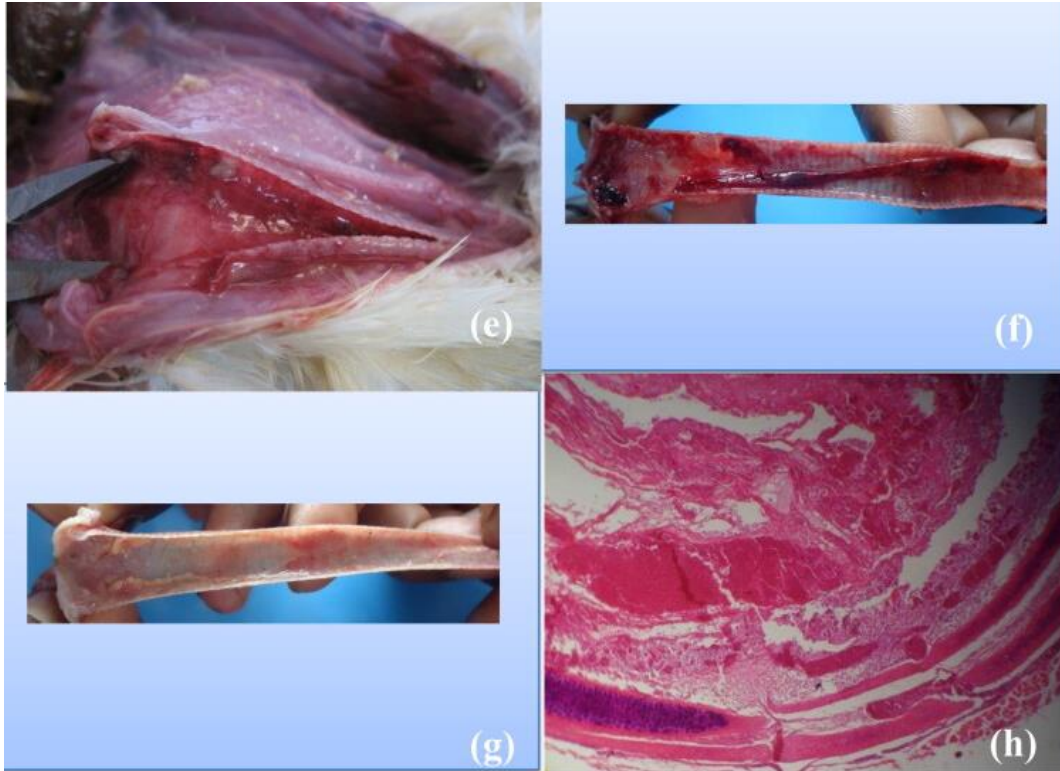
- The mild or chronic ILT resembles with other respiratory infections characterized by **unthriftiness, coughing, moist rales, head shaking, squinting eyes, swelling of the infraorbital sinuses (almond-shaped eyes), drop in egg production (up to 10%), and reduced body weight**. The **morbidity** may go up to 5% and **mortality** usually restricted <2% .

### Gross lesions

- The gross lesions are usually restricted to sinuses and upper respiratory tract and vary with the severity of the disease .
- The gross lesions in peracute form consist of **muroid rhinitis and haemorrhagic tracheitis with blood clots**. **Yellow caseous exudates (cheesy plug)** also observed in **primary bronchi**.



- a. Acutely infected bird shows severe gasping.
- b. Oculo-nasal discharges in early stages of infection.
- c. Facial swelling and persistent oophoria in sub-acute to chronic stage of ILTV infection.
- d. Dried bloody exudates on the commissure of the mouth.
- e. Fibrino-haemorrhagic exudates in the lumen of the trachea.



Gross severely congested and hemorrhagic trachea collected from field ILT outbreaks

## Diagnosis of ILT

Infectious laryngotracheitis in chicken can be tentatively diagnosed based on the clinical signs such as conjunctivitis, gasping, open mouth or extended head respiration, expectoration of bloody mucous, dyspnoea, and finding lesions including catarrhal to hemorrhagic tracheitis, fibrinopurulent to caseous exudates or cheesy or caseous plugs in the larynx and trachea on necropsy.

**Clinical samples** for isolation of ILTV are conjunctiva, larynx, trachea, lung and their exudates. Among the different clinical materials, lungs, tracheal scrapings, and exudates from trachea are ideal for virus isolation.

### 1. Virus Isolation

**Embryonated chicken egg inoculation:** The ILTV is usually isolated and propagated in **9-11 days-old embryonated chicken eggs** through **chorioallantoic membrane (CAM) inoculation**. Opaque plaques can be observed in ILTV infected CAM as early as 48 h post-inoculation and **embryo death occurs between 2 and 8 days post-infection**.

### Animal Cell Culture

The number of primary avian cell cultures, including **chicken embryo liver (CEL), chicken embryo lung, chicken embryo kidney (CEK), and chicken kidney (CK) cell cultures** are **commonly used for ILTV isolation**. The CEL is found to be the most sensitive for ILTV isolation followed by CK. The **cytopathic effects of ILTV infection are characterized by the swelling of cells, chromatin displacement, rounding of the nucleoli and syncytia formation**.

**Intranuclear inclusions are detected as early as 12 hrs post-infection.**

Other culture systems routinely used are **tracheal organ culture (TOC)** and **conjunctival organ cultures (COC)** obtained from chicken embryos or day old chicks. However, these TOC and COC are utilized to study the host pathogen interaction.

2. Apart from virus isolation, the **IF, IP, and immunohistochemistry (IHC)** can be used to detect the ILTV in tracheal tissues and smears.

3. **Agar gel immune diffusion (AGID) technique** using ILTV hyperimmune serum is commonly used to differentiate it from a diphtheritic form of fowlpox . However, the sensitivity was lower when compared with other serological techniques like **virus neutralization test, indirect immunofluorescence test** and **ELISA**.

4. Molecular-based techniques such as PCR, real-time PCR, nested PCR, restriction fragment length polymorphism (RFLP), in situ hybridization have been applied to detect the ILTV because of its high sensitivity, accuracy, rapidity, reproducibility, and simplicity .

## Vaccination

Good biosecurity practices combined with vaccination are the practical methods to control ILTV in the absence of any effective treatment. Nevertheless, ILTV was the first major poultry disease for which an effective vaccine was introduced.

The **modified live attenuated ILTV vaccines including CEO and TCO** have been used for several decades. These vaccines are used for prevention as well as during the phase of an outbreak to control virus spread and shorten its duration.

**Preventive vaccination of ILTV is given at 6 to 8 weeks of age, followed by the booster at 12 to 15 weeks for layers and breeders.** These vaccines elicit the immune response by causing infection in the trachea without producing disease. The highest protective immunity is attained from 15 to 20 weeks post-vaccination, which may last over a year

ILTV vaccination is not suggested for broilers because of its economical concern.

**The route of vaccine administration** has always been critical to ensure protection and avoid adverse vaccine reactions. The **eye drop method** is considered comparatively safer and gives more protection than mass application methods like drinking water and spray administration.

## Control of ILT

- The control measures should be focused on timely diagnosis, implementation of strict biosecurity, cleaning, and disinfection, application of geographic information system (GIS) technology, vaccination, and communication between poultry farmers and control agencies.
- Use of herbal drugs for the treatment of ILTV.
- An effective biosecurity plan includes site quarantine and hygiene, restriction of movement of potentially contaminated workers, equipment, feed, vehicles, and birds.
- Proper disinfectant and litter decontamination should be taken into consideration.
- Preventive measures should also focus on the control of feral birds, rodents, dogs and cats accessing the barns

\*\*\*\*\*