

Herpesviridae

Infectious laryngotracheitis virus, Marek's disease virus

Bovine herpes viruses, Equine herpes viruses, Pseudorabies virus

Malignant catarrhal fever virus, Duck plague virus

Latin Herpein = To creep

Herpesviridae

Group I: dsDNA viruses

Order:

Herpesvirales

Family:

Herpesviridae

Subfamily:

Alphaherpesvirinae

Genus:

Iltovirus

Gallid alphaherpesvirus 1

Infectious laryngotracheitis

Mardivirus

Gallid alphaherpesvirus 2

Marek's Disease Virus

Simplexvirus

Varicellovirus

Suid/porcine Herpesvirus 1

Pseudorabies virus

Subfamily:

Betaherpesvirinae

Genus:

Roseolovirus

Human betaherpesvirus 6A, 6B, 7

Subfamily:

Gammaherpesvirinae

Genus:

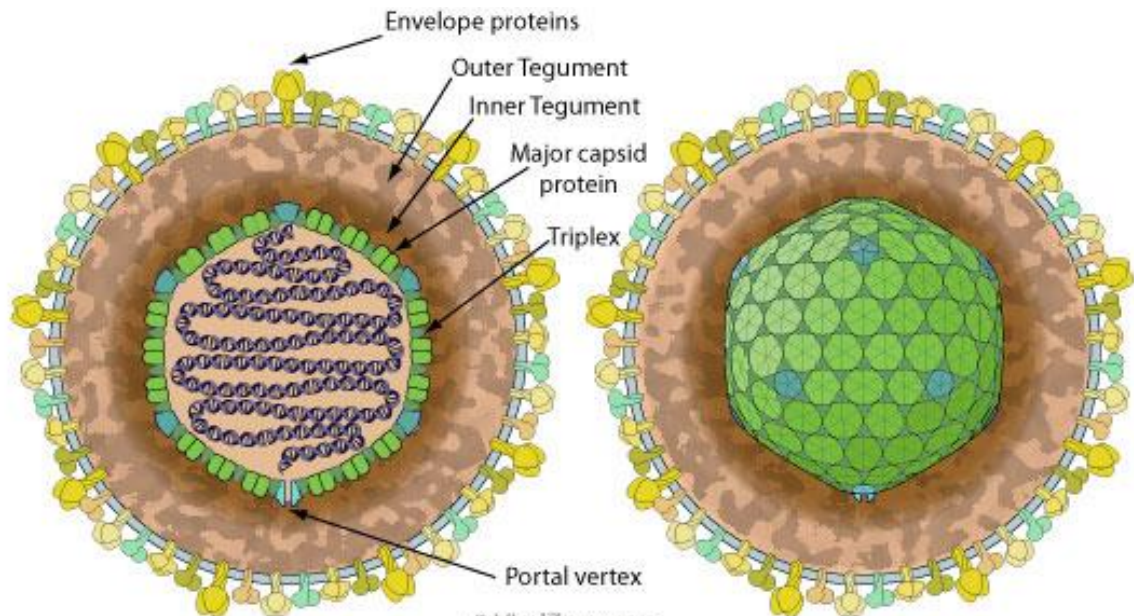
Lymphocryptovirus

Rhadinovirus

Macavirus , *Percavirus*

Herpesviridae

- Enveloped,
- spherical to pleomorphic,
- 150-200 nm in diameter,
- **Icosahedral symmetry.**
- Capsid consists of 162 capsomers and is surrounded by an amorphous tegument.
- Glycoproteins complexes are embed in the lipid envelope.
- Genome-complex consists of **single linear molecule of double stranded DNA**, 125-135 Kbp in size. (Infectious under appropriate experimental conditions).
- Sensitive to chloroform & ether.
- **REPLICATION : NUCLEAR**



Group I: dsDNA viruses

Order:

Herpesvirales

Family:

Herpesviridae

Subfamily:

Alphaherpesvirinae

Genus:

Iltovirus

Gallid alphaherpesvirus 1

Infectious laryngotracheitis

Mardivirus

Gallid alphaherpesvirus 2

Marek's Disease Virus

Simplexvirus

Varicellovirus

Suid/porcine Herpesvirus 1

Pseudorabies virus

Subfamily:

Betaherpesvirinae

Genus:

Roseolovirus

Human betaherpesvirus 6A, 6B, 7

Subfamily:

Gammaherpesvirinae

Genus:

Lymphocryptovirus

Rhadinovirus

Macavirus , *Percavirus*

Marek's Disease



Marek's Disease

Marek's disease is a **highly contagious viral neoplastic disease** in chickens. It is named, a Hungarian veterinarian. It is caused by an **alphaherpesvirus** known after **József Marek** as *Marek's disease virus* (MDV) or *gallid herpesvirus 2* (GaHV-2).

The disease is characterized by the presence of **T cell lymphoma** as well as **infiltration of nerves and organs by lymphocytes**

Birds infected with GaHV-2 can be **carriers and shedders of the virus for life**

Marek's Disease Virus Serotypes

Serotype 1	Serotype 2	Serotype 3
<p>Oncogenic strains</p> <ul style="list-style-type: none"> - GA - MD11 - MD5 - TK - RB1B - etc. 	SB1	HVT
<p>Low Pathogenicity strains</p> <ul style="list-style-type: none"> - CVI988 (Rispens) - Clone C - CR-6 	301B	

Marek's Disease

Properties of MD Virus:

- Enveloped virus,
- MD virus is found in **intracytoplasmic inclusions of feather follicle**, measures 250-280 nm and is **infectious one**, where as that **found in nucleus** measures 150-180nm and presumably is **non-infectious**.
- Show slow CPE i.e., plaque formation.
- **Highly cell associated.**
- **Oncogenic virus.**

Marek's Disease

Association of MDV with non-lymphoid cell results mainly in productive infection, resulting either in the **production of infectious virion** e.g., as in case of **feather follicle epithelium and *in-vitro* cell culture** or in the production of viral antigen, eventually resulting into cell death. Characteristic CPE i.e., Plaque formation is seen (a collection of round refractile cells). Typical intranuclear inclusion bodies are present in infectious cells of cell culture or feather follicle.

Association of MDV with lymphoid cells (tumor cells)

- The transformation takes place resulting in extensive proliferation of cells without cell death.
- There is no expression of viral antigen or virion in the cell.
- There is no *in-vitro* transformation of lymphoid cells by MDV.
- Marek's associated Tumour Specific Antigen (**MATSA**) is present only in infected lymphoid cells.
- MDV is antigenically related with Herpes Turkey Virus HVT-1 which is non-oncogenic to chicken and turkey and doesnot spread horizontally among chickens.

Marek's Disease

- The virus replicates to the fully infectious form in the feather follicles
- The route of infection is the respiratory system by inhaling infectious viral particles
- Tumors (lesions) occur due to the malignant transformation of the lymphocytes

Marek's Disease

Pathogenesis:

Chicks exposed on day of hatching develops the disease in about 3 weeks.

Birds carrying B21 alloantigen of RBC group are naturally resistance to MDV infection.

Mature virus particle (enveloped) is formed only in feather follicle is shedded into the environment through desquamated cells (dander), Maximum shedding of virus is seen at 5-6 weeks post infection.

Infection is acquired by inhalation of dander.

Epithelial cells of respiratory tract are infected ,productively develops **cell associated viraemia** involving macrophages.

On 6th Day **productive infection of Lymphoid cells** in variety of lymphoid organs (i.e., thymus, Bursa of Fabricius, Bone marrow, spleen, etc.). Resulting in immunosuppression.

II nd week transformation-**T lymphocytes are transformed by the virus resulting into proliferation of T- Lymphocytes.**

(lesions of feather follicle are invariably a mixture of lymphoblastoid and inflammatory cells).

Marek's Disease

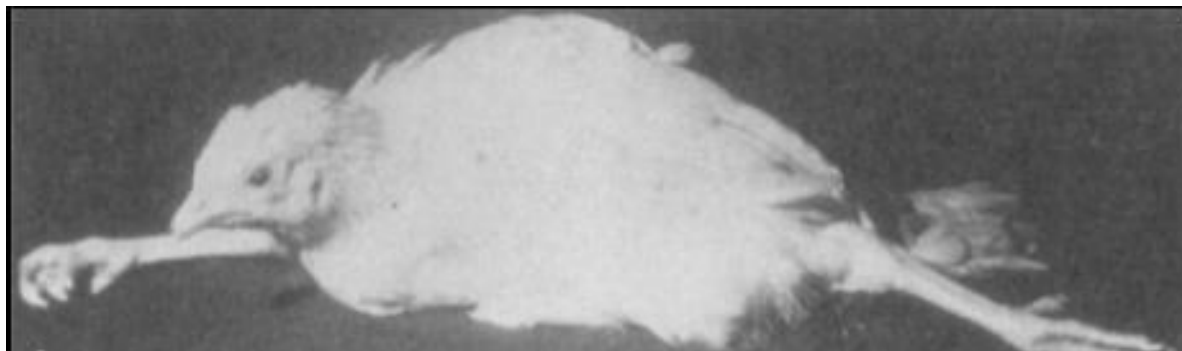
Clinical Signs of MD

MD is a progressive disease with variable clinical signs.

The clinical picture of MD is described in four overlapping syndromes:

Neurolymphomatosis:

- 'Classical MD' is associated with **asymmetric paralysis of one or both legs/wings**.
- Inco-ordination is common early sign.
- **One leg is held forward and the other in backward in direction.**
- When stationary because of **unilateral paresis or paralysis**.
- Wing dropping, lowering of head and neck is seen commonly.
- If the vagus nerve is involved then dilation of crop and gasping is seen.



Marek's Disease



Paralysis

Marek's Disease

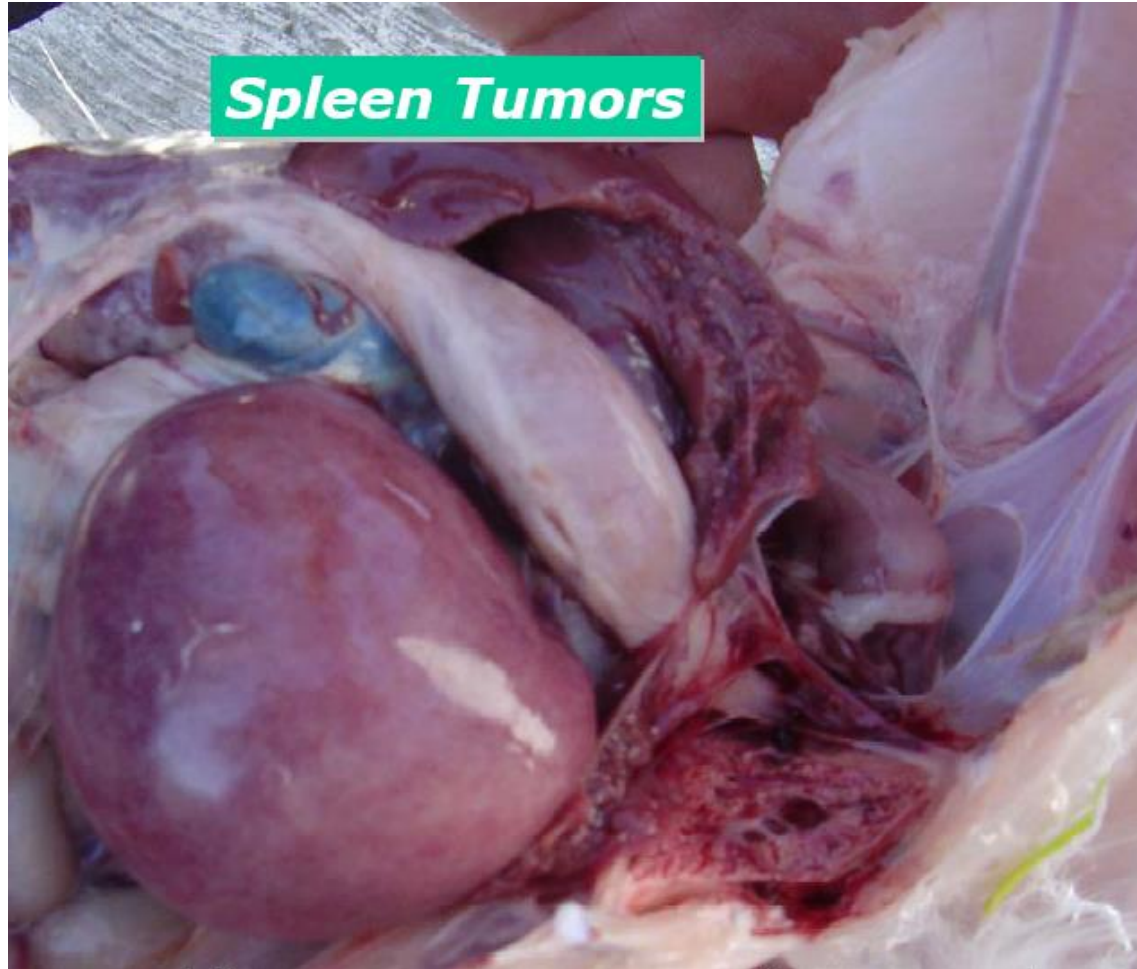


Marek's Disease

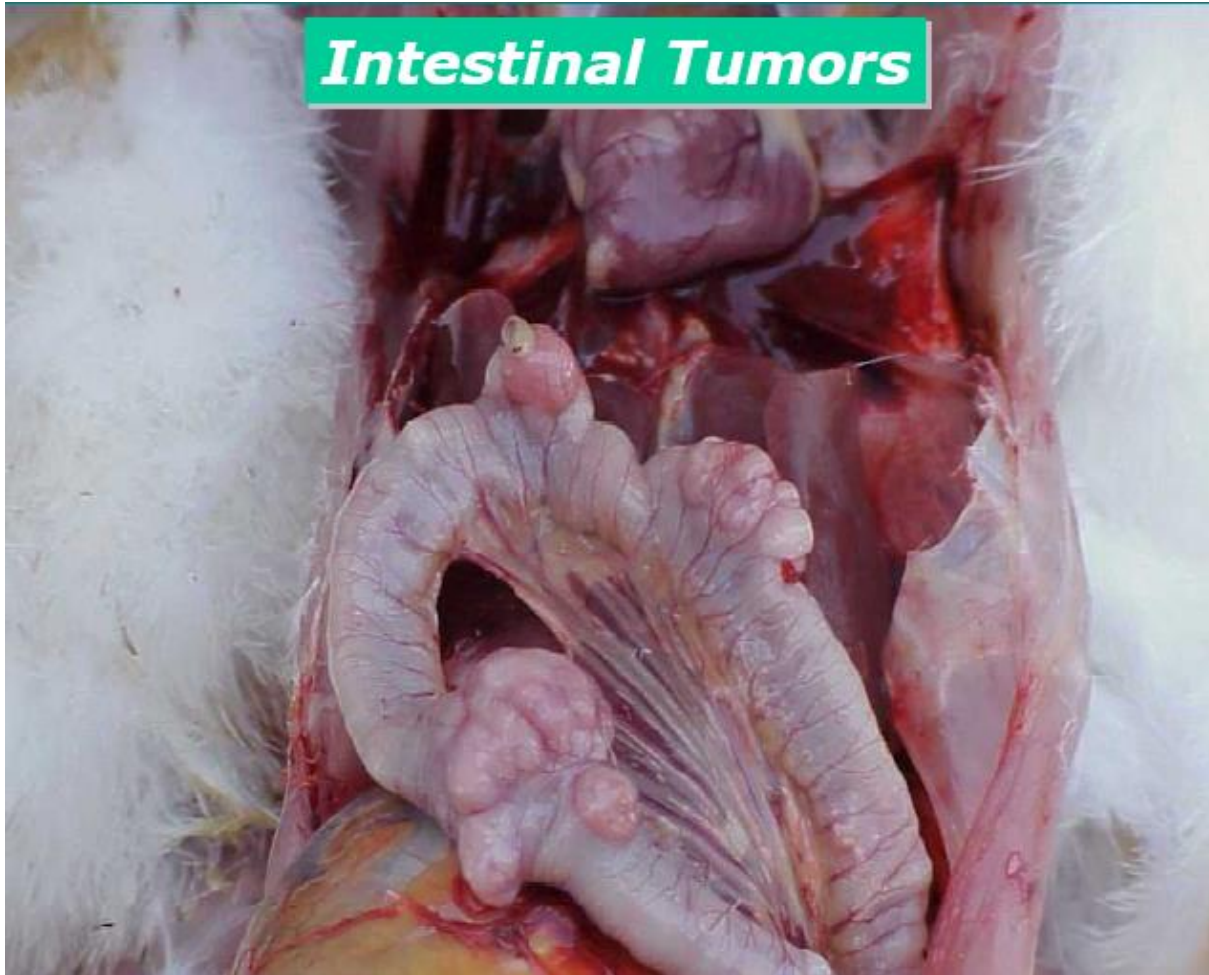Visceral Form / Acute form of Marek's Disease:

- Depression followed after a few days by ataxia & paralysis in some birds.
- Significant mortality, occurs without localizing neurological signs.

Marek's Disease



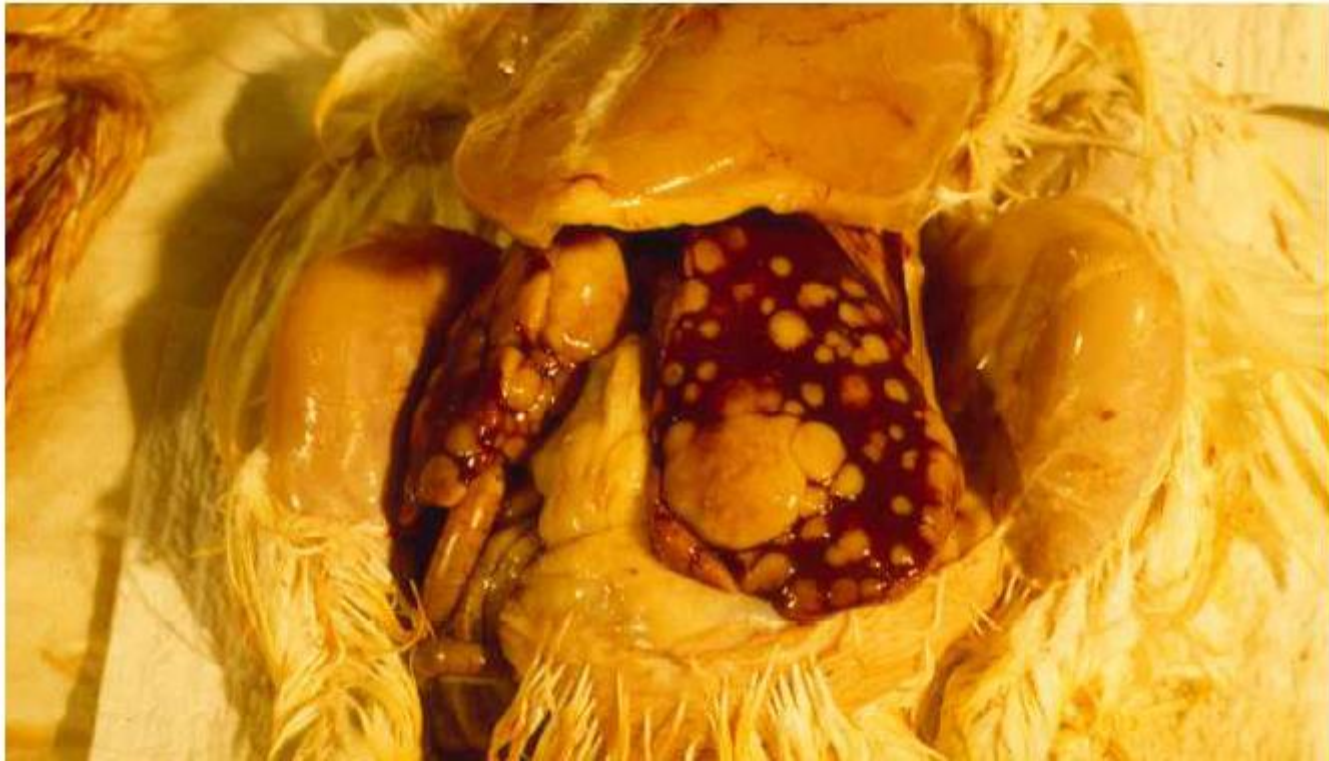Marek's Disease



Marek's Disease

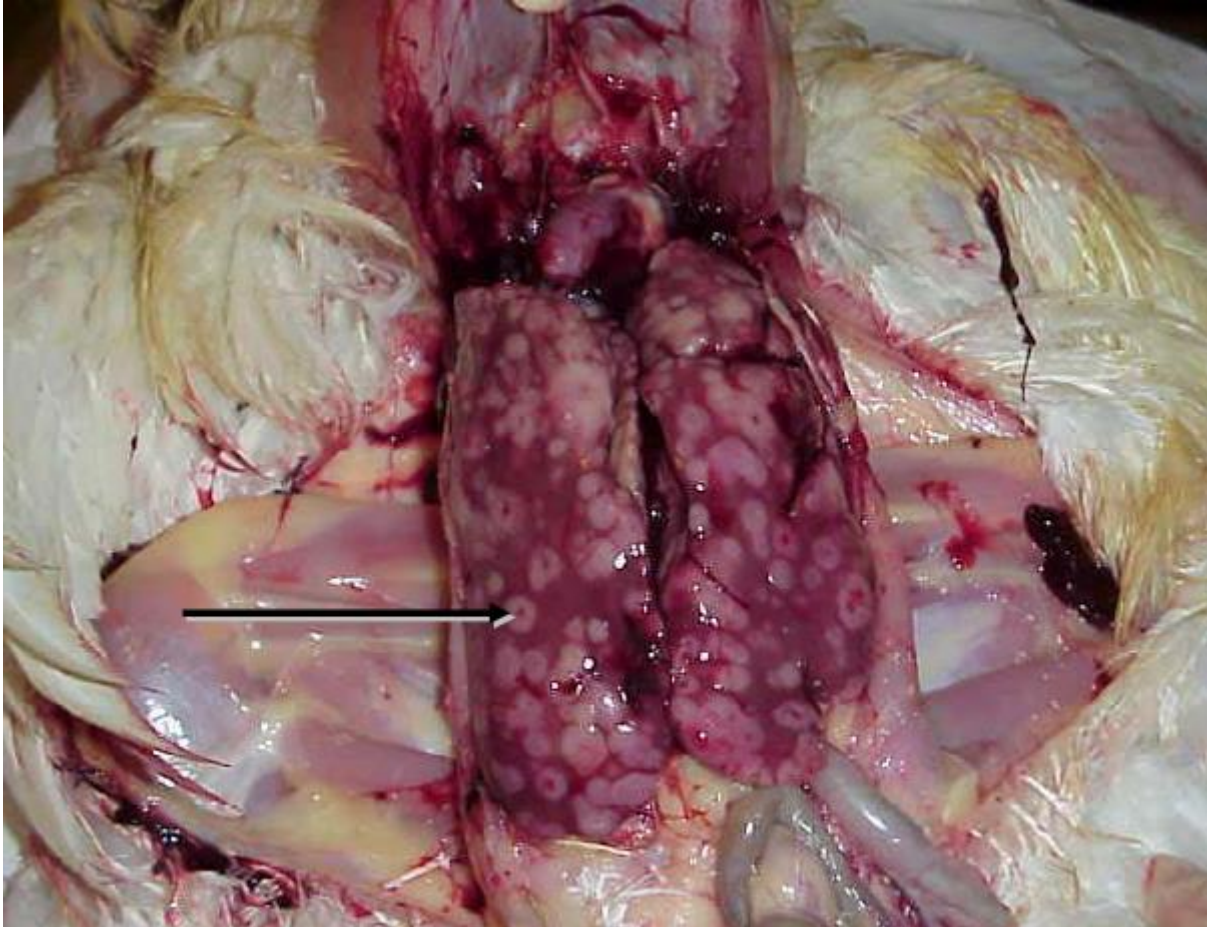


Marek's Disease



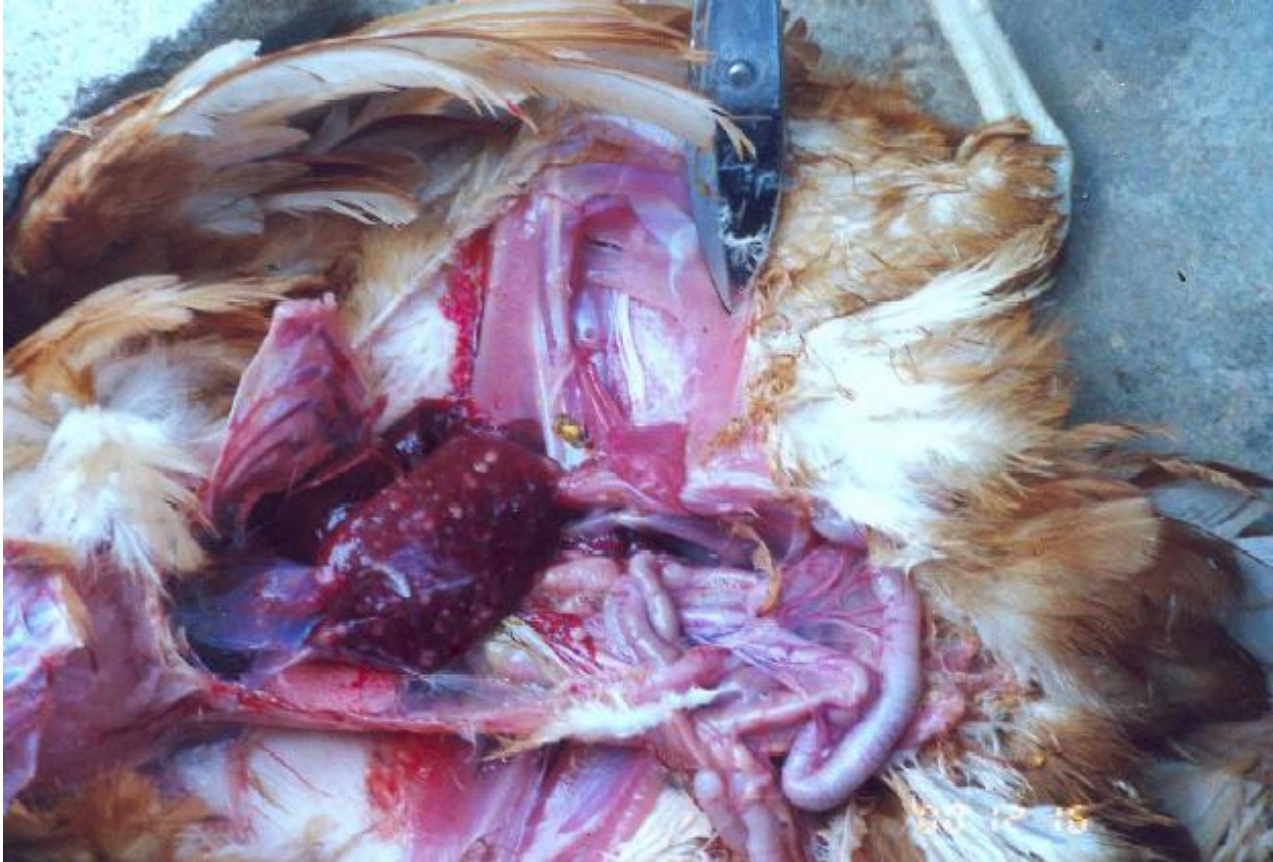Liver Tumours

Marek's Disease



Liver Tumours With Necrotic Centres

Marek's disease

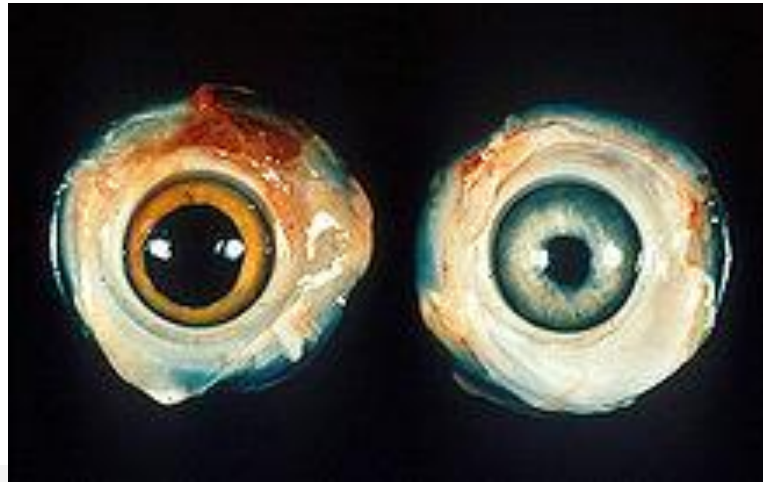

Liver Tumours In Layers

Marek's disease

Ocular Lymphomatosis:

Leads to graying of the iris of one or both eyes because of lymphoblastoid cell infiltration, the pupil is irregular and eccentric and there may be practical or total blindness.

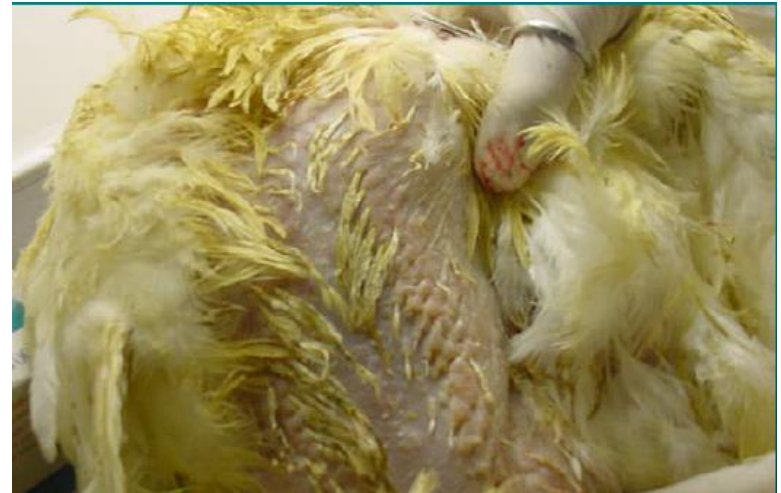

Left - normal chicken eye. Right - Eye of a chicken with Marek's disease

Marek's disease

Cutaneous Marek's Disease:

Is recognised readily after plucking, when round, nodular lesions upto 1 cm in diameter is seen at feather follicle base.



Marek's disease

Pathological Findings in MD:

In case of

Highly oncogenic strain- Lymphoid tumours affecting the gonads (ovary), pale and infiltrated with the lymphoid tumour tissue.

There is characteristic **bursal and thymic atrophy**.

Lymphoid tumours are indistinguishable from those of ALC, are usually smaller, diffuse, grayish, translucent.

Non-oncogenic strains produce neither of above.

Nerve lesions are the most characteristic findings in affected bird.

Nerves enlarge upto 3 times their normal diameter, show loss of striations become edematous, grayish/yellowish. Some what translucent and the enlargement is frequently **unilateral**.

The peripheral nerves are enlarged and intensely infiltrated with immature mononuclear cells, striations, **thickening of sciatic nerve, brachial nerve**, intercostal, mesenteric and greater splenchnic nerve.

Discolouration of iris, pupil is irregular **owing to infiltration of mononuclear cells**.

Marek's disease

Immunology:

- The protection is attributed to CMI response.
- The MAb protects the chick upto 3 weeks of age.
- It is believed that on vaccination, chicken develop transitory lymphoproliferative lesions containing **MATSA** and a CMI response directed against the **MATSA** probably protects them against subsequent lymphoma formation by MDV.

Marek's disease

Laboratory Diagnosis:

1. Diagnosis can be made based on history, age, clinical signs and gross post-mortem findings.

2. Detection of viral antigen by **immunofluorescence** is the simplest reliable laboratory diagnostic procedure.

3. Gel diffusion, indirect immunofluorescence or VNT is used for the detection of viral antibodies.

4. Isoaltion of MDV can be isolated by inoculation in chicken kidney or duck embryo fibroblast cell cultures with intact viable cells from buffy coate, spleen tumour tissue or other lymphoid cells or feather tip (which contains cell free virus). Characteristic **plaques appears in the infected cell cultures in 5-10 days.**

5. Differential Diagnosis

Disease Parameter	Marek's Disease	Avian Leucosis
Etiology	Gallid Herpesvirus 2	Retrovirus
Target Cells	T Lymphocytes	Various Haemopoietic Cells
Age of onset of signs	4 weeks	16 weeks
Paralysis	Yes	No
Gross Lesions		
Liver ,Spleen,Kidney	Yes	Yes
Gonads, Lungs,Heart	Yes	Rare
Nerve Trunks	Yes (Neural Form)	Rare
Iris	Yes (Ocular Form)	Rare
Skin	Yes (Cutaneous Form)	Rare
Bursa of Fabricius	Rare	Yes (Nodular)
Microscopic Lesions		
Size of affected lymphoblasts	Varied	Uniform
Intranuclear inclusion bodies	Yes	No

Marek's disease

Prevention and Control of Marek's Disease:

Vaccination is the principal method of control of MD.

The standard method has been to **vaccinate 1 day old chicks parenterally or in-vivo on 18 th day of incubation.**

HVT-1, Naturally apathogenic , non oncogenic strain of MDv and cell culture associated attenuated . All three types are equally protective but

HVT-1 is most extensively used because it is more economical to produce.

The vaccine is available either a lyophilised cell free preparation or cell associated preparation.

The cell free vaccine doesnot '**Take In**' in chicks with maternal antibodies, where as cell associated vaccines do.

The vaccine virus doesnot prevent superinfection, replication or shedding of virulent MDV , but do prevent illness/disease and tumour formation. Protective immunity develops within 2 weeks and persists for life.

Marek's disease

Preferred **HVT-1 virus** for vaccine doesnot spread horizontally and has a poor vertical spread, hence each chicken must be vaccinated individually.

The **mechanism of vaccination is attributed to CMI response.**

It is believed that vaccinated chicken develop transitory lymphoproliferative lesions containing MATSA and a CMI response directed against this MATSA probably protects them against subsequent lymphoma formation by MDv.
e.g., HVT-1 Vaccine SB1 Cell Associated Vaccine etc.

'All-In-All-Out' Principle would improve the efficacy of vaccination as control measures.

Most commonly Used MD Vaccination Programs

Program	Broilers	Layers	Broiler Breeders
1	HVT	HVT+Rispens	HVT+Rispens
2	HVT+SB1	HVT+Rispens +SB1	Rispens

Vaccine Administration

Marek's disease



Subcutaneous vaccination at one day of age

Marek's disease

Material Send to the Laboratory:

Live Birds in acute stage of disease,
Feather Follicles from Chest and neck regions in any
transport medium,
Paired Sera samples &

For Histopathology

Portions of peripheral nerve, trachea, ovary, kidney, spleen
and skin in 10 % neutral formal saline solution.

PSEUDORABIES

(Aujeszky's Disease, Mad Itch, Infectious bulbar paralysis)

Aujeszky's disease is caused by a virus that can remain latent and causes respiratory, reproductive and nervous problems.

PSEUDORABIES

Pseudorabies is an acute, frequently fatal disease with a worldwide distribution that **affects swine** (serves as reservoir) primarily and other domestic and wild animals incidentally.

Secondary Host: Cattle, Sheep, goats, dogs, horses, cat & many ferret species.

Porcine Herpes Virus Type 1

- DNA Herpes virus
- 150-180nm in diameter
- Enveloped
- Thermostable 60°C for 50 minutes
 - 70°C for 10 minutes
 - 80°C for 03 minutes
 - 100°C virus killed instantly
- Resist 3% Phenol, but 5% phenol kills virus in 2 hours
- Survive for 2-7 weeks in infected premises/meat.
- Grow readily in rabbit, Guinea pig testicular cells, chicken embryo fibroblast & pig kidney cells.
- 1%NaOH destroy virus immediately.
- Putrefaction destroys virus in 11 days.

Transmission

- **Swine**-Primary Host & Reservoir for Pseudorabies virus
- Virus shed in saliva and nasal discharges of swine-licking, biting and aerosols .
- Virus is not shed in urine or faeces. Ingestion of contaminated feed, infected carcass-pork- most common sources of infection for secondary hosts.
- Rats and ferrets contribute to farm to farm transfer & probably the source of infection for dogs and cats.

PATHOGENESIS- PSEUDORABIES

Primary oral or intranasal infection of swine

Virus replicates in oropharynx

No viraemia (during first 24 hours)

Virus spread by cranial nerves (via axoplasm) and olfactory nerves

Spread to central nervous system
(Ganglioneuritis at many sites)

Viraemia

PATHOGENESIS- PSEUDORABIES

- No characteristic lesions are found
- Congestion of nasal mucosa, pharynx, lungs, haemorrhages and edema.
- Tonsillitis, Pharyngitis, tracheitis, rhinitis, oesophagitis.
- Small Necrotic foci on liver and spleen.
- Diffuse nonsuppurative meningoencephalitis, necrosis of neuronal/ganglionic cells.
- **Type A intranuclear inclusions** found in respiratory tract and CNS.

CLINICAL FEATURES PSEUDORABIES

Swine:

Younger pigs are more severely affected but become more resistant as they age. Very young neonates may die without signs even having been noticed.

Nursing pigs usually show signs of **neurologic involvement**, high fever, depression, anorexia, tremors, incoordination, dog-sitting position, vomiting, foaming at the mouth, blindness, paddling, coma and convulsions. Death often occurs within one to three days. Morbidity and mortality may approach 100% in neonates.

Weaned pigs (three to nine weeks of age) have similar signs but **mortality is usually much lower**. Respiratory signs often occur in the older pigs of this age group. They include **sneezing, nasal discharge, sometimes coughing and labored breathing**. Most of the pigs survive.

Abortion in pregnant sow.

CLINICAL FEATURES PSEUDORABIES

Cattle:

Characteristic Sign- Intense Pruritis

Vicious rubbing, intense scratching-area become abraded.

Animal becomes frenzied.

Encephalitis, Paralysis ,COMA, Death.

Progressive involvement of CNS leading to death
m/b as short as few hours and is never longer than 6
days.

Laboratory Diagnosis **PSEUDORABIES**

1. **Clinical Picture**
2. **Serological Tests:** VNT,AGPT,CFT & ELISA
3. **Virus Isolation:** Pocks on CAM, Polykaryocytes-Infected cell culture
4. **FAT**
5. **Animal Inoculation:** Rabbit-Intense pruritis and death within 3 to 6 days.
6. **PCR**
7. **Histopathological Examination:** Type A intranuclear inclusion bodies.

PSEUDORABIES

Prevention & Control

1. Preventing the entry of virus into farm
2. Farrow to Finish

3. Vaccination:

Intranasal vaccination of sows and neonatal piglets 1-7 days old, followed by I/M vaccination of all other swine on the premises, helps reduce viral shedding and improve survival.

THANKS

